

Silent Inflammation in the Jaw and Neurological Dysregulation - Case Study Linking Rantes/Ccl5 Overexpression in Jawbone with Chemokine Receptors in the Central Nervous System

Johann Lechner^{1*} and Volker Von Baehr²

¹Clinic for Integrative Dentistry, Grunwalder Str. 10A, 81547 Munchen, Germany

²Compartment of Immunology and Allergology on Institute for Medical Diagnostics in MVZ GbR, Nicolaistrasse 22, 12247 Berlin, Germany

This article was published in the following Scient Open Access Journal:
Journal of Dental and Oral Health

Received January 31, 2017; Accepted March 07, 2017; Published March 16, 2017

Abstract

Background and Introduction: The transition from acute local inflammation following wisdom tooth surgery to a chronic stage of “Silent Inflammation” could be a neglected cause of unexplained medical conditions.

Case Report: Here we will refer to an unusual case of recurrent syncope in a 19-year-old woman whose 12 months of treatment in various clinics, and wide range of prescribed medications, failed to bring about any improvement in her condition.

Material and Methods: As previous analyses of the cytokine profile in fatty-degenerative osteonecrosis of the jawbone (Fdoj) show local overexpression of the chemokine Rantes/Ccl-5 (R/C), this case further supports the suspicion of a chronic inflammatory process.

Results: Stepwise surgical removal of Fdoj areas containing insufficiently healed, osteonecrotic medullary cavities resulted in the permanent cessation of syncope episodes by removing local sources of r/c.

Discussion: Following a study of the relevant literature on the effects of chemokines in the central nervous system (Cns), We focus here on the interconnected disease pathways of peripheral R/C overexpression and disorders of the Cns. A change in peripheral immune regulation in the jaw provokes a chronically aggressive immune response in the Cns. If both systems fail to resume normal functioning, this maladaptation results in a dire neurological response pattern in this young patient.

Conclusion: The incomplete wound healing and associated “Silent Inflammation” in the jawbone may contribute via peripheral, local R/c overexpression to various symptoms in the Cns which are typical of chemokine's. From a systemic perspective, we recommend that more attention be paid to this cytokine cross-talk in medicine and dentistry.

Keywords: Rantes/Ccl5, Fatty-Degenerative Osteonecrosis of the Jawbone, Syncope, Central Nervous System, Cytokine Cross-Talk, Silent Inflammation

Background

With the increasing complexity of various systemic diseases, it is appropriate to discuss the background of their pathogenesis. Autonomic dysregulation with poorly defined multisystem disorders frequently present a challenging clinical situation for medical practitioners [1,2]. With the absence of any discernable cause, together with insufficient research on this increasingly prevalent phenomenon, many presentations of this form of “idiopathic multimorbidity” are often eventually assumed to be of psychogenic origin, and pharmacological interventions in the form of psychoactive substances are common [3,4]. A case study from our dental practice* supports the need for a wider pathogenetic perspective in cases of neurological dysregulation. Here, we will describe a case of recurrent syncope in a young woman. Her case demonstrated the typical symptoms, namely fainting with a brief loss of consciousness and muscular strength, characterised by rapid and unpredictable onset, short duration, and Spontaneous Recovery. Given The Unclear Aetiology, We Associate This Case With The Phenomenon Of Avascular And Aseptic Osteolytic, Inflammatory Processes In The Jaw, Which May Also Be Collectively Referred To As “Silent Inflammation”.

*Clinic for Integrative Dentistry, Gruenwalder Str. 10A 81547 Munich, Germany

*Corresponding Author: Johann Lechner, Clinic for Integrative Dentistry, Grunwalder Str. 10A, 81547 Munchen, Germany, Tel: 0049-89-6970129, Email: dlechner@aol.com

The Clinical Case

We will be using the remarkable medical history of 19-year-old female patient C. To illustrate the systemic interconnections of persistent dental wound healing impairments from a clinical perspective. c. First experienced a loss of consciousness in the time between two wisdom tooth extractions, On October 21, 2008 and December 18, 2008 respectively. In the following months, the number of syncopal incidents increased rapidly, leading to her admission to a clinic where she was diagnosed with postural orthostatic tachycardia syndrome (pots) and a disturbance of the autonomic nervous system. Numerous Medications (See Below) Brought No Improvement. After multiple further tests, the patient was discharged as a "Psychological Case". Approximately one year later, it was "normal" for C. To lose consciousness several times a day, and she was no longer able to leave the house unaccompanied. Her losses of consciousness resulted in daily falls with painful injuries, including a concussion which required several days of bed rest. By the time she attended our practice in March 2010 for an evaluation of possible sites of inflammation in her jaw, C., aged 19, required a companion whenever she went anywhere public: she needed someone to reassure bystanders and avoid unnecessary calls to the emergency services.

Summary of Clinical Investigations, Findings and Treatments

Although the patient had a history of surgical removal of four impacted wisdom teeth - the only notable event preceding the onset of her syncope episodes - Internists, Neurologists, and psychiatrists did not consider the possibility of any remaining wound healing disorders in the area of the wisdom teeth. A total of ten internal, neurological, and psychiatric evaluations (Emg/Eng, Multiple Sleep Latency Test, Etc.) were carried out in the period from June 2009 to January 2010, including two hospital admissions in university teaching hospitals. The Diagnosis of "Pots and Orthostatic Hypertension" was made repeatedly. The patient received several months of treatment with Efectin®, A Serotonin-Noradrenalin Reuptake Inhibitor (Snri); Astonin H®, A fludrocortisone approved for hormone replacement in various forms of adrenal insufficiency as well as for the short-term treatment of low blood pressure; and Mestinon®, A Cholinesterase Inhibitor With Application in Paroxysmal Tachycardia; and also With Gutron®, Beta Blockers, and Euthyrox®. Other proposed treatments included yoga therapy and moderate physical activity with the use of compression stockings C. was last examined by a specialist in psychiatry and psychotherapeutic medicine on November 11, 2009, who made a diagnosis of "Recurrent Falls Due To Dissociation," noting that "The previous diagnosis of pots, from a clinical history perspective, as well as epileptic events, is extremely unlikely or atypical." He recommended the "Rigorous thematisation of psychosomatic connections with continuation of accompanying psychotherapy consultations." After almost a year of examinations, hospital stays, and unsuccessful medical treatments with hormones, antidepressants and beta-blockers, the patient experienced no noticeable reduction in the frequency of her seizures. Socio-Therapeutic supervision by an attendant was considered necessary for the 19-year-old, as C. was significantly restricted in her mobility and safety outdoors due to her frequent syncope episodes.

Materials and Methods

Diagnosis of "Silent Inflammation" in the Jaw

Following a period of hospitalisation, the patient brought a two-dimensional orthopantomogram (2d-Opg) to our practice for the purpose of evaluating the possibility of any inflammatory processes in the teeth and jawbone area; this showed no anomalies or suspicious indications of "Silent Inflammation" Or Osteolysis in the areas of the wisdom teeth that had been removed one year previously (Figure 1). Diagnostic radiology could not establish any specific context for the patient's symptoms.

In previous publications, we have referred to the insufficient diagnostic representation of "Silent Inflammation" in the form of Fdoj in the jawbone [5]. The 2d X-Ray technique alone is unsuitable for making a reliable exclusion-based diagnosis of Fdoj. However, complementary "Through-Transmission Alveolar Ultrasonography" (Tau) is appropriate for diagnostic imaging of Fdoj [6]. Tau diagnosis enables targeted detection and, based on this, the treatment of osteonecrotic and ischaemic areas of medullary alveolar bone [7].

Morphology of Fatty-Degenerative Osteolysis of the Jawbone

In areas of Fdoj there is irregular bone, with thinned and hollowed out cancellous bone and medullary cavities. Clinically and macroscopically, Fdoj often presents as fatty clumps of tissue. Notably, there is a complete absence of trabecular cancellous bone structures. Figure 2 shows an intraoperative tissue sample with

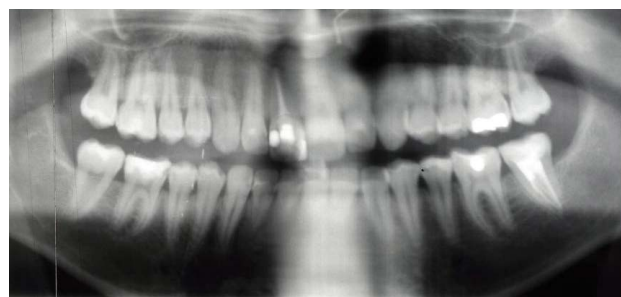

Figure 1: Unremarkable 2d-Opg from December 2009, with no findings in the areas of the extracted wisdom teeth 38 and 48.

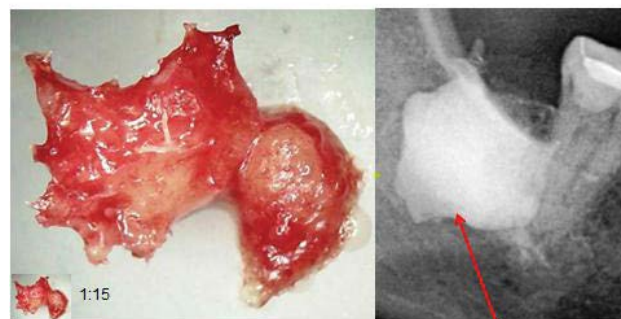
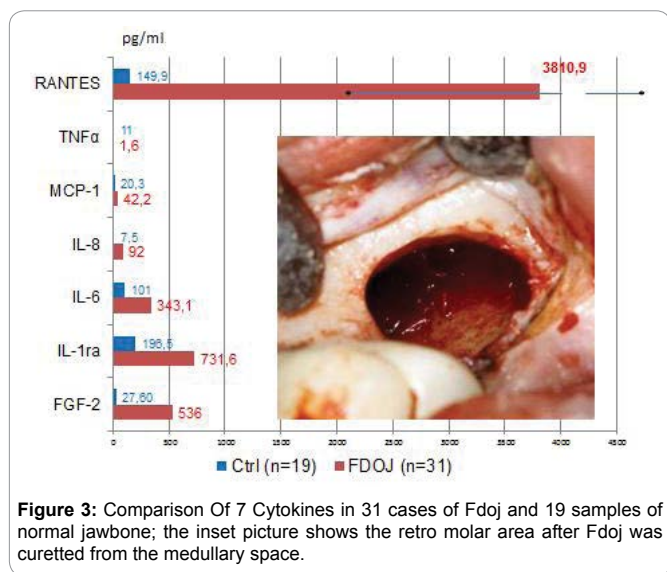


Figure 2: Left-Hand Image: Typical Fatty-Degenerative structure of Fdoj. Right-Hand Image: Documentation of the expanse of Fdoj in retromolar area 48/49 with contrast agent following Fdoj surgery, comparable to the case described here.



the predominantly fatty transformation of cancellous bone (Left-Hand Image). The consistency of Fdoj indicates that, in addition to metabolic disorders, local hypoxic-ischaemic conditions are also present, preventing even the slightest autonomic tendencies to heal. The Right-Hand Image in Figure 2 indicates the extent of Fdoj in retro molar area 48/49 as shown by contrast agent following typical Fdoj surgery [5].

Hyperactivated Immune Mediators in Osteolytic Jawbone

In Previous Studies [8] we were able to determine a 21-Fold increase in Rantes/Ccl5 (R/C) expression in 31 Fdoj samples compared to a normal jawbone (Nj) (see Figure 3). The Pathologically altered Fdoj samples of 31 jawbones were obtained predominantly from the wisdom tooth and retro molar areas (the so-called 9-areas). The samples of Fdoj with a volume of up to 0.5 Cm³ were removed and immediately placed in a dry, sterile receptacle (Sarstedt Mikro-Tube; Ref.: 72.692.005), Hermetically Sealed, And Stored At -20°C Until Transported To The Laboratory**. Here, the Fdoj samples were mechanically broken down into small particles and resuspended and homogenized in 200 µl of protease buffer (Complete Mini Protease Inhibitor Cocktail, Roche, D). The homogenate was centrifuged for 15 Minutes At 13,400 Rpm, and the supernatant was centrifuged for a further 25 Minutes At 13,400 Rpm. R/C was determined in the supernatant of the tissue homogenate with human cytokine/chemokine panel I (Mpxhcyto-60k; Millipore GmbH, Schwalbach, Germany) according to the manufacturer's protocol, and measured on a Luminex® system (Emd Millipore, Billerica, Ma, Usa).

** Institute for Medical Diagnostics, Nicolaistr. 22, 12247 Berlin Www.lmd-Berlin.De

A total of 7 Cytokines were measured in Fdoj tissue obtained from the Fdoj Group (N=31). The distribution and concentration of immune mediators show the clear prevalence of Il-1ra, Fgf-2 and, particularly, Of R/C. The available data suggest that additional focus should be placed on further interpreting the R/C Data; The mean value of R/C in the Fdoj samples was 3,977.21

(Pg/ML), and the median was 3,810.90 with a standard deviation (sd) of 2,566.99. These significant correlations, as well as the consistently high R/C values in Fdoj tissue, were observed in all 31 samples. This can be seen as an indication of specifically deranged metabolism in Fdoj, with repeatedly occurring and mutually reinforcing patterns of pathogenetic signal transduction. The concentration and distribution of cytokines in normal cancellous jawbone (N=19) was (In Pg/ML) as follows: For Fgf-2, 27.6; For Il-1ra, 195.5; For Il-6, 101.0; For Il-8, 7.5; For Mcp-1, 20.3; For Tnf, 11; and for R/C, 149.9. No comparative values were found in the literature for these mediators in healthy jawbone. Figure 3 compares the mean values of 19 healthy bone samples (blue) with the medians of 7 cytokines from 31 Fdoj samples (Red). The inset image shows the retro molar area after curetting Fdoj from the medullary space in this case.

The Absence of an elevation in the proinflammatory, acute cytokines Tnf-A and Il-6 in the Fdoj samples demonstrates that Fdoj is a gradual and chronic sub threshold process. Thus, Fdoj areas may be clearly defined as osteolytic regions of the jaw with an inflammatory burden. These Fdoj characteristics, with implicit R/C overexpression, were present in all Four of C.'S wisdom tooth areas. The systemic significance of R/C is presented in the discussion.

Histology of Fdoj Surgical Areas

The histological evaluation of area 38-39 in the case of C. is very subtle and reads as follows: "Vital, somewhat irregular cancellous osseous tissue without evidence of active bone remodelling. In the medullary spaces, in addition to internal bleeding, there is also evidence of moderate, chronic, so-called osteitis. No florid Inflammation, No Osteomyelitis. The fat cells show partially myxoid transformation or vacuolar degeneration of the cytoplasm which is consistent with trophic disorders." The typical indicators of fatty degeneration of Fdoj are present, but at the same time, there is only a moderate inflammatory tendency without the clinical significance of osteomyelitis. This histology is characteristic of fdoj, i.e., the long-term transition from an acute infectious wound to chronic inflammation.

Results of Jawbone Remediation from March 2010 to August 2010 in the Case of Recurrent Syncope

In the case of patient C., Following local anaesthesia and the folding over of the mucoperiosteal flap, the cortical layer was removed at tooth 37 and the edentulous regions of the jaw at 38/39, 48/49, 18/19, And 28/29, Each In a separate procedure. Underneath, instead of normal, structured cancellous bone, typical Fdoj tissue was present. After careful curettage of the softened parts of the medullary cavity the wound was primarily closed and primary intention healing followed. The patient reported her observations in writing on September 15, 2010: "When Dr. L Removed the first of four areas of the detected wound healing disorders in my jaw in March 2010, the immediate result was a week without syncopes! Since then the number of syncopes has continuously decreased" (See Figure 4). The four main remediation phases proceeded as follows:

- a) Immediately after the first surgical procedure at 37/38/39, In which the root-filled tooth 37 was removed and Fdoj sites in the region 37/38/39 were surgically debrided, the frequency of syncope episodes decreased to

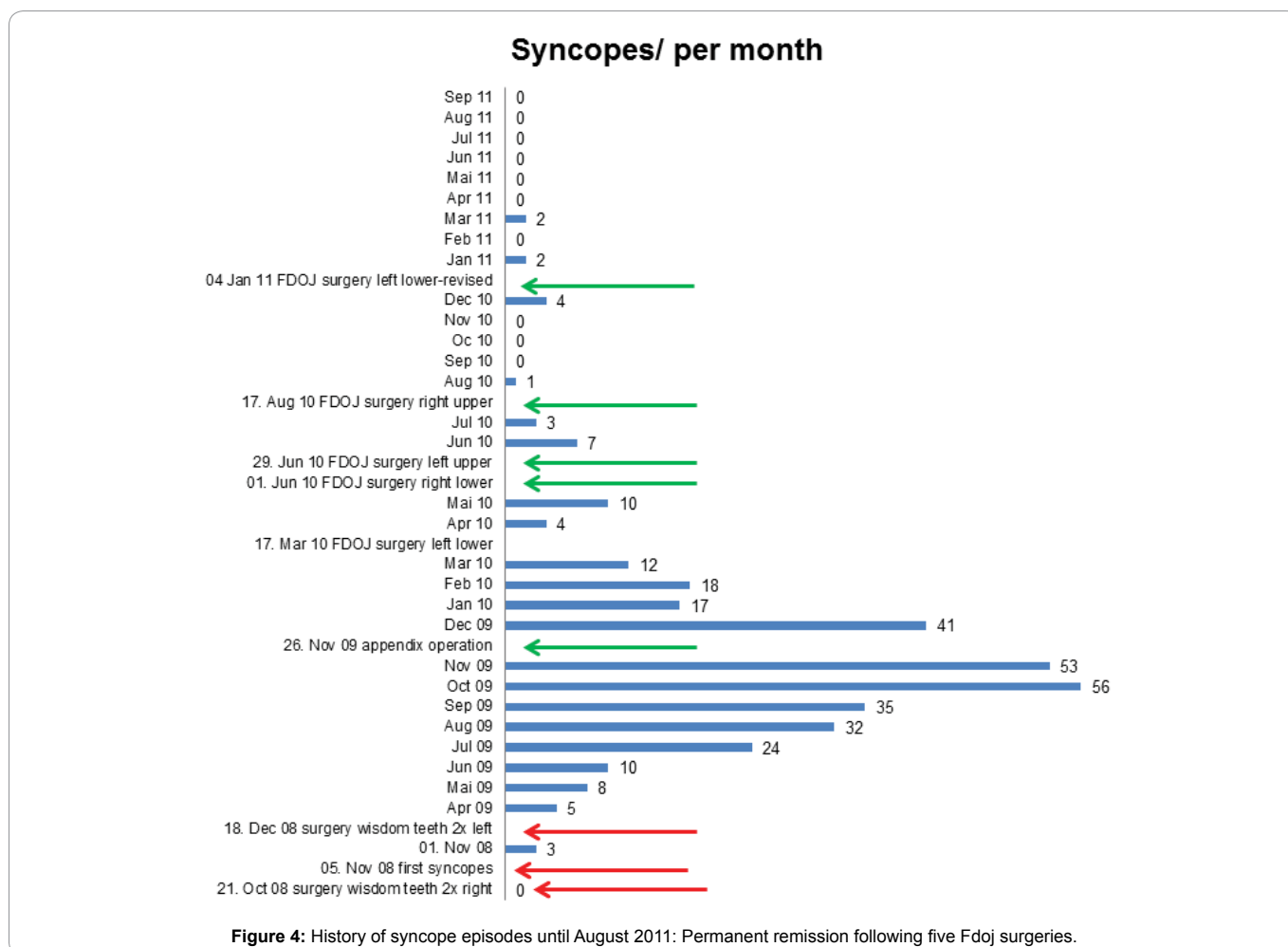


Figure 4: History of syncope episodes until August 2011: Permanent remission following five Fdoj surgeries.

once per week, but subsequently increased again.

- b) Following the surgical curettage of area 48/49 in June 2010, the frequency of syncope episodes decreased, but then increased once again.
- c) In the four weeks following a revision procedure at 37/38/39 In August 2010, C. Fell only once (compared to 2-5 times per day in the previous two years) despite having a painful wound which had not yet healed.
- d) On the penultimate weekend of September 2010, C. Hiked in the mountains for the first time in two years without a single syncope episode.

Two aspects of this case are noteworthy. Firstly, contrary to the 2d-Opg, the tau image immediately shows the pathogenically causal Fdoj in the wisdom tooth areas. In contrast to the unremarkable X-ray images, there were extensive sites of softened and necrotic cancellous bone in the areas of Fdoj which were entirely asymptomatic for the person concerned. In this area of conflict, the development of a Trans-Alveolar Ultrasonic (Tau) Scan for the imaging of bone density represents a significant step forward in the diagnosis of suspected Fdoj [6]. Secondly, following the removal of patient C.'s chronically inflamed appendix on November 26, 2009, there was a reduction in the frequency of syncopes. In the observation report of Figure 4, the patient

documented the disappearance of syncope episodes along the time axis. The reduction in syncopes, therefore, was not solely the result of the surgical elimination of Fdoj in the wisdom tooth regions, but from the sum total of inflammatory triggers resolved. In July 2013, C. reported those six months previously her driver's license had been returned to her.

Discussion

In the following section, we will attempt to discuss the pathophysiological concept of Fdoj based on patient C's case. The central concern is the transition from an acute inflammation of a dental surgical wound to a chronically inflamed area of the jaw rather than a "Restitutio Ad Integrum". When the initial pathogenic condition cannot be resolved by the immune system, a chronic inflammatory response may sometimes result. This is the case, for example, when tissue becomes fibrotic following a wound healing disorder. Initially, Macrophages, Inter Alia, attempt to eliminate the source of inflammation. If this fails, macrophages can also run another program and stimulate fibroblasts which induce the conversion to inactive connective tissue. This condition occurs, for example, in acute osteomyelitis following antibiotic therapy in the transition to chronic osteomyelitis: after antibiotic therapy, inflammation may persist for many months, possibly even years. A biopsy during this phase only indicates fibrosis with chronic inflammatory cells, I.E., No neutrophil granulocytes are detected.

The bone may be vital and hence show immature, fibrotic tissue with only some fat cells and a few scattered lymphocytes [9].

The morphological structure of Fdoj is likely to be accompanied by an advanced state of chronic inflammation, during which a decoupling takes place of the usually temporally coordinated homeostatic processes between the immune and neuronal super systems, preventing a return to the normal situation. It is also conceivable that entire areas of communication may be excluded from the organism's regulatory mechanisms as a whole in this manner. Such decoupled areas of communication would then be isolated and clinically normal healing would be impeded [9]. The systemic response of the organism subsequently manifests in a neuroendocrine entanglement of immune and wound healing responses with devastating consequences for the rest of the organism. Certainly, other etiological factors are also involved in chronic systemic inflammatory disorders. These include genetic polymorphisms; environmental factors Such As Microbes, Toxins, Cultural Background, Etc.; and immune responses in the form of individual overreactions [10]. Accordingly, a uniform inflammatory response in the case of impaired wound healing cannot be expected due to the different emerging variables, but rather constant changes in inflammatory markers [11].

Transition from Acute Wound Infection to Chronic Inflammation

In chronic inflammation, the production of cytokines by infiltrating local tissue cells overwhelms and exceeds the body's regulatory mechanisms. This results in tissue destruction, either directly or indirectly, via the activation of immune and inflammatory cells which, for example, induce the production of inflammatory cytokines and proteases involved in tissue destruction. It is generally accepted that a disparity between cytokines and their respective inhibitors is characteristic of chronic inflammatory conditions. Cytokines are involved in the initiation of an immune response, the induction of acute inflammatory events, and the transition to, or persistence of chronic inflammation. This means that the mechanisms of cytokine production must be controlled in order to maintain a healthy homeostatic state [12]. In the affected areas of the jaw, fdoj exhibits a deranged metabolism and the associated chronic inflammatory signal transduction cascades, primarily by R/C overexpression. This jeopardises the continuation of normal cellular signal transduction and results in persistent disorders of metabolic and immunological homeostasis. These chronic stress stimuli may be accompanied by diseases and comorbidities associated with a local Fdoj Inflammatory status. The interconnections of Fdoj with neuralgiform or systemic-immunological disease patterns may also be related to the role of the nervous system as a signal integrator of the locally disrupted metabolic homeostasis in the medullary cavity of the jawbone. At the same time, Fdoj represents a novel inflammatory phenomenon, since the cellular response is initiated by neither a bacterial nor viral trigger, but rather a persistent metabolic and signal transduction derangement. Studies by Happel, et al. [13] demonstrate that the extremely high R/C levels we find regularly in edentulous jaw regions and old extraction areas may indicate a late phase of incomplete wound healing. The cytokine Tgf-B is liberated during wound healing and at sites of inflammation in the acute phase. Tgf-B appears to be a precondition for the induction and upregulation of R/C expression. The studies demonstrate

that Tgf-B1 significantly induces R/C expression, but does not increase the production of Ccl-2.

Systemic Effects of the Chemokine Rantes/Ccl5

R/C is a chemotactic cytokine with proinflammatory action. The significance of R/C to the development of disease appears to be immense: R/C interferes with immune responses at several stages and is thus substantially involved in infections or pathological conditions. The chemotactic properties of R/C recruit T-Cells, Dendritic Cells, Eosinophils, Natural Killer (Nk) Cells, Mast Cells, and basophils to sites of inflammation and infection. R/C is also a potent activator of leukocytes, which play a key role in a wide range of inflammatory disorders [14]. The dysregulation Of R/C expression often leads to a self-reinforcing effect that causes a critical condition in the body [15]. Immunohistochemical studies of various tissues have shown that r/c is only very weakly expressed in healthy adult tissue. As soon as an inflammatory tissue response occurs, however, the proportion of r/c-positive cells increases dramatically [16]. The highly inflammatory mediator potential of r/c from Fdoj areas suggests that these jawbone osteolyses may be regarded as carriers of "Neo-Self Epitopes". The resulting systemic response is mediated via cytokine-driven and mediator-based "Signalling Pathways" with the additional involvement of activated immune cells and sensory nerves. In the adipose tissue typically present in Fdoj Areas, the number of sympathetic nerve fibres decline, while the sensory nerve fibres increase. This conclusion correlates with hundreds of histological findings in the Fdoj areas we have examined. Notably, the following wording is consistently used in the description of the findings: "... In the immediate vicinity of these myxoid degenerative changes, preserved, intact, small neuronal branches may be identified."

Fdoj Areas Become Immunologically Effective "Neo-Self Epitopes"

The current understanding of autoimmune processes is associated with the apparently non-inflammatory processes of apoptosis and linked to the effects of the inefficient clearance of cellular components. These processes may present neo-antigens to the immune system within Fdoj. Dead and defunct cells are usually removed quickly and effectively via apoptosis. In some autoimmune diseases, however, this cleaning mechanism is impaired, resulting in the accumulation of dead and dying cells for an extended period of time [17,18]. As a consequence, these cells serve as targets for autoantibodies in many autoimmune diseases. In addition, these remaining dead cells release signalling substances which trigger a systemic immune response [19]. For example, the induction of chemokines - such As R/C - occurs as part of a post-infarction inflammatory response [20].

Immunogenicity, I.E., the ability of a molecule to elicit an immune response, generally differs from substance to substance; thus, weak and strong immunogens exist. Epitopes are the molecular parts of an antigen that can trigger a specific immune response. Individual factors with respect to the person concerned, such as pre-existing stressors, gender, age, and possible genetic polymorphisms, play a role as to whether such epitopes lead to a loss of tolerance and the development of autoimmune diseases. Alterations in the structure or sequence of amino acids can form so-called neo-epitopes of endogenous "Self"-Proteins. Such neo-epitopes trigger auto-aggressive immune attacks, which

can then lead to sustained, possibly pathogenetic, signalling pathways. Studies have shown that altered lipoproteins within fatty-degenerative portions of fdoj areas stimulate the expression of proinflammatory cytokines and lead to increased antigen presentation, resulting in the development of additional tissue lesions. impaired and ischaemic metabolic states - as typically represented in Fdoj - lead to the formation of intracellular reactive oxygen species (ros) and to the further secretion of cytokines, as well as to R/C overexpression [21].

Since several of the aforementioned parameters are applicable in the case of Fdoj, it is possible to conclude that Fdoj may be a carrier of neo-self epitopes which has remained relatively unnoticed. Firstly, Fdoj areas typically contain modified and denatured proteins and necrotic cells, whose molecular parts may serve as antigens which trigger a specific immune response. Secondly, Fdoj is an ischemic area with resulting elevated Ros. Thirdly, Fdoj and its antigen presentation are structures which are newly formed from necrotic adipocytes or altered proteins and lipids, and which do not form part of a healthy cancellous jawbone. In addition, the morphological changes in Fdoj are accompanied by altered patterns of immunomodulators (R/C, Inter Alia) with adaptive immune responses; These patterns become independent "Self" components of a systemic autoimmune derailment. On the basis of the fatty-degenerative tissue alterations and the overexpression of immune mediators, Fdoj largely fulfils all the parameters of an immunological definition, namely that which is described in the literature as "Neo-Self Epitopes".

Chemokine-Induced "Silent Inflammation" in the Cns

Since cytokines are barely able to penetrate the blood-brain barrier, the way in which they are able to induce inflammatory reactions in the brain has remained a mystery until recently [22-24]. chemokines and their receptors are located throughout the brain. Among the chemokines and their receptors, which are arranged in glial cells and neurons, are, among others, the monocyte chemotactic protein (Mcp)-1/Ccl-2 And R/C [25]. Within the brain, they are found in the Hypothalamus, Limbic System, Hippocampus, Thalamus, Cortex, and Cerebellum [26,27]. In addition to anatomical, immunohistochemical, and in vitro studies, there is a growing body of research suggesting that there is a crucial role for the chemokine system in the brain.

A considerable amount of data suggests that this chemokine system can result in alterations in the effects of neuronally active substances. Combined with the evidence that the chemokine system in the brain interacts with the neurotransmitter system, this leads to the following hypothesis: the endogenous chemokine system in the brain regulates brain function in coordination with neurotransmitter and neuropeptide systems. The chemokine system can thus be regarded as a third member of the large transmitter systems in the brain [28,29]. Neurotransmitter and neuropeptide systems interact in the brain, and it is therefore logical to postulate that the chemokine system also interacts functionally with these two other neuronal systems. This provides indications of significant functional modulation of neuronal processes by chemokines and their receptors, and it supports the assumption that chemokines play a clear role in neuronal communication. The endogenous chemokine system in the brain, consisting of ligands and receptors, is a third important system of the brain. Hence, there is certainly no longer a doubt

that chemokines provide important functions in the brain and comprise neuroactive compounds that have direct and indirect effects on neurons [28]; they also play an unexpected role in the normal physiology of the brain [29].

The Search for immunological biomarkers in psychiatric disorders has focused primarily on proinflammatory cytokines. The activation of mast cells results in the upregulation of numerous chemokines in the brain, such as R/C [30], leading to an expansion of proinflammatory response profiles in microglia [31]. Chemokine receptors and adhesion molecules are used specifically for transendothelial migration of leukocytes across the Blood-Brain Barrier (Bbb) in neuroinflammatory Processes. A significant increase in the migration of mononuclear cells across the bbb was observed in response to increased R/C [32]. The function of the chemokine system may be of particular interest to hematogenous leukocyte infiltration of the Cns due to the specific nature of Cns inflammation and the extraordinary specificity with which the chemokine system regulates cellular migrations. The analysis of the chemokine system promises insight into the inflammatory mechanisms and responses of the Cns. However, the complexity of neuroinflammation is matched by the diversity and multitude of chemokines and chemokine receptors [33].

Conclusion

This case study details firstly, the limited phenomenon of adolescent syncope and, secondly, the chronic inflammatory changes in the jawbone in the form of prolonged wound healing disorders following wisdom tooth extraction. We focus here on the interconnection between the jawbone and the central nervous system via chronic, subclinical inflammation. In doing so, we draw attention to the question of whether certain dental procedures may be responsible for the development of otherwise inexplicable systemic inflammatory reactions. The medical background of our case study suggests the need to integrate sterile-aseptic, cavity-forming osteolysis of the jawbone/fdoj [7,8] into an immunopathogenetic trigger model in the case of neurological dysregulation. The problem of the systemic cross-linking of fdoj becomes chronic when local inflammation of the healing wound becomes chronic and fdoj triggers chemokine overexpression. This process has very little in common with the original bone structure of a perfect "Healing" and "Restitutio Ad Integrum". As a consequence, fdoj triggers a systemic response, this derangement results from a permanent wound response in the transition to fibrotic scarring with antigen-presenting cell components and overexpressed signalling transduction by r/c. It is proposed that this case study should guide the implementation of a standardised clinical procedure in which appropriately selected patients can be evaluated for Fdoj. The appropriate surgical removal of fdoj is recommended as concomitant therapy where applicable. In order to clarify reliable causal genetic backgrounds this study can only indicate the direction in which extensive further research and clinical observations are necessary.

List of Abbreviations

2d-Opg = Two-Dimensional Orthopantomogram

Bbb = Blood-Brain Barrier

Ccl5 = C-C Motif Chemokine 5-Chemotactic Cytokine or Chemokine

Cns = Central Nervous System

Fdoj = Fatty-Degenerative Osteonecrosis of the Jawbone

Fgf-2 = Fibroblast Growth Factor-2, Growth Factor

Il-1ra = Interleukin-1 Receptor Antagonist

Il-6 = Interleukin-6

Il-8 = Interleukin-8

Nj = Normal jawbone

Mcp-1 = Monocyte Chemotactic Protein-1

Pots = Postural Orthostatic Tachycardia Syndrome

R/C = Rantes/Ccl-5

Rantes = Regulated Upon Activation, Normal T-Cell Expressed, and Secreted

Tau = Trans-Alveolar Ultrasound

Acknowledgments

Translation and English-Language Editing of this Manuscript were provided by Natasha Gabriel.

References

- Hawkes N. Better training is needed to deal with increasing multimorbidity. *BMJ*. 2012;344:E3336.
- Barnett K, Mercer SW, Norbury M, Watt G, Wyke S, Guthrie B. Epidemiology of multimorbidity and implications for health care, research, and medical education: A cross-sectional study. *Lancet*. 2012;380(9836):37-43.
- Smith SM, Wallace E, O'Dowd T, Fortin M. Interventions for improving outcomes in patients with multimorbidity in primary care and community settings. *Cochrane Database Syst Rev*. 2016;14:3.
- Jakovljevic M, Reiner Z, Milicic D, Crncevic Z. Comorbidity, multimorbidity and personalized psychosomatic medicine: epigenetics rolling on the horizon. *Psychiatr Danub*. 2010;22(2):184-189.
- Lechner J. Validation of dental X-ray by cytokine RANTES - comparison of X-ray findings with cytokine overexpression in jawbone. *Clin Cosmet Investig Dent*. 2014;6:71-79.
- Bouquot Je, Shankland We li, Margolis M: Through-Transmission alveolar ultrasonography (Tau) - new technology for evaluation of bone density and desiccation. Comparison with radiology of 170 biopsied alveolar sites of osteoporotic and ischemic disease. *Oral Surg Oral Med Oral Pathol Oral Radiol Endod*. 2002:93.
- Lechner J, Von Baehr V. Peripheral Neuropathic Facial/Trigeminal Pain and Rantes/Ccl5 in Jawbone Cavitation. *Evidence-Based Complementary and Alternative Medicine*. 2015.
- Lechner J, Von Baehr V. RANTES and Fibroblast Growth Factor 2 in Jawbone Cavitations: Triggers for Systemic Disease? *Int J Gen Med*. 2013;6:277-290.
- Bouquot JE, Roberts AM, Person P, Christian J. Neuralgia-inducing cavitation osteonecrosis (NICO). Osteomyelitis in 224 jawbone samples from patients with facial neuralgia. *Oral Surg Oral Med Oral Pathol*. 1992;74(3):348-350.
- Straub RH, Cutolo, M, Zietz B, Scholmerich J. The Process Of Aging Changes The Interplay Of The Immune, Endocrine And Nervous Systems. *Mech Ageing Dev*. 2001;122(14):1591-1611.
- Eggleton P, Haig R, Winyard PG. Consequence of neo-antigenicity of the 'altered self'. *Rheumatology*. 2008;47(5):567-571.
- Lee S, Zhao YQ, Ribeiro-da-Silva A, Zhang J. Distinctive response of CNS glial cells in oro-facial pain associated with injury, infection and inflammation. *Mol Pain*. 2010;6:79.
- Happel C, Steele AD, Finley MJ, Kutzler MA, Rogers TJ. Damgo-induced expression of chemokines and chemokine receptors: the role of Tgf-B1. *J Leukocyte Biology*. 2008;4:956-963.
- Levy JA. The unexpected pleiotropic activities of Rantes. *J Immunol*. 2008;182:3945-3946.
- Appay V, Rowland-Jones SI. Rantes: a versatile and controversial chemokine. *Trends Immunol*. 2001;22(2):83-87.
- von Luetlichau I1, Nelson PJ, Pattison JM, et al. Rantes chemokine expression in diseased and normal human tissues. *Cytokine*. 1996;8(1):89-98.
- Baumann I, Kolowos W, Voll RE, et al. Impaired uptake of apoptotic cells into tingible body macrophages in germinal centers of patients with systemic lupus erythematosus. *Arthritis Rheum*. 2002;46(1):191-201.
- Donnelly S, Roake W, Brown S, et al. Impaired recognition of apoptotic neutrophils by the C1q/Calreticulin and Cd91 pathway in systemic lupus erythematosus. *Arthritis Rheum*. 2006;54(5):1543-1556.
- Matzinger P. The Danger Model: A Renewed Sense of Self. *Science*. 2002;296(5566):301-305.
- Frangogiannis NG. The mechanistic basis of infarct healing. *Antioxid Redox Signal*. 2006;8(11-12):1907-1939.
- Miller, Choi SH, Wiesner P, et al. Oxidation-Specific Epitopes Are Danger-Associated Molecular Patterns Recognized By Pattern Recognition Receptors Of Innate Immunity. *Circ Res*. 2011;108(2):235-248.
- Rothwell NJ, Hopkins SJ. Inflammatory response: pathway across the blood-brain barrier: how cytokines can induce these effects has been a mystery as they are unlikely to cross the blood-brain barrier. *Trends Neurosci*. 1995;18;130-136.
- Salgado A, Boveda JL, Monasterio J, et al. Inflammatory mediators and their influence on haemostasis. *Haemostasis*. 1994;24(2):132-138.
- Ek M, Engblom D, Saha S, Blomqvist A, Jakobsson PJ, Ericsson-Dahlstrand A. Inflammatory Response: Pathway Across The Blood-Brain Barrier. *Nature*. 2001;410(6827):430-431.
- Adler MW, Rogers TJ. Are Chemokines The Third Major System In The Brain? *J Leukoc Biol*. 2005;78(6):1204-1209.
- Van Der Meer P, Ulrich AM, Gonzalez-Scarano F, Lavi E. Immunohistochemical analysis Ofcrr2, Ccr3,Ccr5, and Cxcr4 in the human brain: potential mechanisms for HIV dementia. *Exp Mol Pathol*. 2000;69(3):192-201.
- Horuk R, Martin AW, Wang Z. Expression of chemokine receptors by subsets of neurons in the central nervous system. *J Immunol*. 1997;158(6):2882-2890.
- Bajetto A, Bonavia R, Barbero S, Schettini G. Characterization of chemokines and their receptors in the central nervous system: physio- pathological implications. *J Neurochem*. 2002;82(6):1311-1329.
- Tran PB, Miller RJ. Chemokine receptors in the brain: A developing story. *J Comp Neurol*. 2003;457(1):1-6.
- Feuser K, Thon KP, Bischoff SC, Lorentz A. Human intestinal mast cells are a potent source of multiple chemokines. *Cytokine*. 2012;58(2):178-185.
- Skuljec J, Sun H, Pul R, et al. Ccl5 induces a pro-inflammatory profile in microglia in vitro. *Cell Immunol*. 2011;270(2):164-171.
- Ubogu EE, Callahan MK, Tucky BH, Ransohoff RM. Determinants of Ccl5-driven mononuclear cell migration across the blood-brain barrier. Implications for therapeutically modulating neuroinflammation. *J Neuroimmunol*. 2006;179(1-2):132-144.
- Ransohoff RM. The chemokine system in neuroinflammation: an update. *J Infect Dis*. 2002;186(Suppl 2):S152-156.